Spontaneous Osteonecrosis of the Knee (SONK)

Information for Healthcare Professionals

Pathophysiology of Osteonecrosis

Spontaneous osteonecrosis of the knee (SONK) has a unilateral pattern of distribution, typically affecting a small area of subcortical bone of the medial femoral condyle, but more rarely the medial tibial plateau. This condition is characterized clinically by a sudden onset of severe pain in the knee joint, often persisting at rest and worse at night. It occurs most commonly in older females and is associated with medial meniscal tears, osteoarthritis and osteoporosis, but not systemic disorders or corticosteroid therapy. This pattern contrasts with that of the better understood secondary or classic osteonecrosis of the knee, which is associated with prolonged corticosteroid use, alcohol consumption, rheumatoid arthritis, systemic lupus erythematosus, sickle-cell disease, Caisson's disease and Guacher's disease.

The terms Avascular Necrosis (AVN), OsteoNecrosis and Spontaneous Osteo-Necrosis (SONK) are often interchanged but SONK refers to a specific primary condition as outlined.

Secondary osteonecrosis is often distributed bilaterally, and involves the lateral femoral condyle in 60% of cases. Characteristically, there is an insidious onset of mild pain around the knee joint, and no association with age or gender. On MRI scans, secondary osteonecrosis lesions appear wedge-shaped and much larger than in SONK. The distinct clinical presentations, risk factors and radiological findings suggest that SONK is an aetiologically distinct form of osteonecrosis; a notion first proposed by Sven-Olof Ahlback, a Swedish radiologist, in 1968.

The exact aetiology of SONK remains controversial, but one hypothesis for which there is growing evidence is that SONK is the result of a subchondral insufficiency fracture in osteoporotic bone. Other factors that may play a role in initiating SONK include meniscal damage, which could cause uneven weight distribution and loading, and chondromalacia associated with osteoarthritis. The mechanism of initiating SONK is impairment of the collateral circulation to the subchondral bone, which leads to hypoxia, ischemia and subsequent oedema. Oedema creates an increase in intraosseous pressure, further impeding the blood flow and worsening the ischemia and necrosis.

Sometimes SONK follows within 2 months of arthroscopy and the surgery has been linked to the cause. The evidence for this is however very limited and overall it is considered that arthroscopy is very unlikely to cause SONK.

Diagnosing SONK

A history of sudden onset severe knee pain, present at rest and during the night, without a traumatic inciting stimulus, is characteristic of SONK. Examination usually reveals pain around the medial femoral condyle, effusion, range of movement limited by pain or swelling, and potentially tenderness on deep palpation of the medial joint line. Occasionally there is tenderness over the medial aspect of the femoral condyle. The cruciate and collateral ligaments are usually stable, but tests for meniscal integrity, including McMurray's test, may be positive. A thorough history and physical examination are required to detect risk factors for SONK and secondary osteonecrosis, and eliminate differential diagnoses. Differential diagnoses include osteochondritis dissecans, primary osteoarthritis, meniscal injury, bone

bruises, transient osteopenia of the knee, stress fracture, primary bone malignancy, bone metastasis and pes anserinus bursitis.

Investigations should include

- Radiology: The first line investigation of acute non-traumatic knee pain is plain film radiography in lateral and standing anterior-posterior orientations. Radiographs usually fail to show changes in the early period after the onset of pain, but later may show subchondral radiolucent areas, flattening of the femoral condyle, and in advanced cases sclerosis and secondary osteoarthritic changes.

- MRI: MR imaging is the gold standard for detecting SONK, being more sensitive than radiographs and bone scanning, allowing earlier and more detailed indication of subcortical bone and bone marrow abnormality. On T1-weighted MRI, SONK is seen as a focal or diffuse hypo-intense signal in the subcortical region of the femoral condyle (or tibial plateau), where the normal high intensity fat signal has been replaced by the dark signal of marrow oedema and necrosis. On T2-weighted images the lesion appears hyper-intense. Usually an insufficiency fracture can be seen as a linear dark signal margin between the normal and necrotic bone on both T1 and T2 weighted sequences.

- Blood tests: To help identify secondary causes tests should include FBC, ESR, CRP, U&E's, LFT's, Calcium, Cholesterol, Serum Ferritin, clotting screen, immunoglobulins, and Auto-immune profile.

Treatment of SONK

SONK is usually progressive, resulting in joint destruction as the subchondral bone collapses within three to five years if left untreated. However, evidence suggests that osteoporosis and medial meniscal tears are associated with SONK, therefore enhanced surveillance of osteoporosis and early treatment of meniscal tears in older patients in the future might reduce the progression of SONK.

There are three main treatment options for SONK:

- Conservative management
- Core Decompression
- Joint replacement

<u>Conservative treatment</u>

Conservative treatment involves: touch weight-bearing with crutches, analgesia, NSAID's, and physiotherapy to strengthen the quadriceps and hamstring muscles. Touch weight-bearing is the most important aspect of conservative management as it immediately relieves loading pressure on the knee joint, improves blood flow, and hence promotes tissue healing and prevents joint collapse.

This regimen must be followed for a minimum of six weeks, with good results expected where the osteonecrotic lesion is small and symptoms are mild to moderate. Patients will find that their pain rapidly improves once weight is taken off the leg and will be tempted to return to weight bearing early. The issue of remodelling of the underlying supportive bone needs to be explained to the patient and the protection must continue for 6 weeks. This is followed by avoiding any impact sport for up to 6 months and often a repeat MRI scan is performed during that time to check on resolution.

Core decompression

Knee joint preservation is the ultimate treatment aim in patients with SONK, retaining maximum function in daily activities and sports, and preventing secondary osteoarthritic changes to joint surfaces. 'Core decompression' is one type of joint preserving surgery which has demonstrated positive results. The surgery involves making a small incision and using a 2-3mm drill or guide wire to make several holes in the affected area of bone. This immediately reduces the pressure in the joint by allowing some excess fluid to drain away. Blood supply to the joint is improved, preventing further necrosis and collapse.

The benefits of core decompression over conservative treatment include faster recovery time, with surgery offering almost immediate pain relief, and reduced future requirement for arthroplasty. This is a quick and relatively safe procedure, though possible complications include infection, fracture, and failure to eliminate pain.

Failure to relieve symptoms is more common where the condition is in its late stages and the area of osteonecrosis is large. For this reason core decompression is usually only advised in the early stages of SONK. Following the procedure there must be touch weight-bearing only on the affected knee for six weeks, after which progression to full weight-bearing is typical.

There is good evidence in the literature that performing decompression in the first 4 weeks will probably alter the natural history of the condition and prevent progression. It is certainly extremely effective at taking away the pain. What there is not in the literature is any good guide as to the technique. We choose to use a long 2.4mm guide wire from the ACL instrumentation and make 4 – 8 drill passages in the affected area under image intensifier control. The MRI scan needs to be studied carefully in order to obtain a clear mental 3-dimensional image of the geographical location prior to analysing and planning aiming based on image intensifier views. In that way an appropriate starting point on the opposite or same side of the femoral shaft can be planned. It seems logical to try and start the drilling from a position well outside of the abnormal area. See the images below as a case example.

Joint replacement

In more severe cases where part of the joint has undergone collapse, joint replacement surgery may be the favourable option. Unicompartmental knee arthroplasty to replace the compartment affected by SONK is preferred over total knee replacement, particularly in younger adults, as it preserves the rest of the knee joint. Joint preservation is particularly important where total knee arthroplasty may be needed in later life and there is good evidence in the literature to support its use.

Prognosis

The prognosis for an individual with SONK varies depending on a number of key factors. The size of the necrotic subchondral lesion carries the greatest prognostic value, but pain severity and the stage at diagnosis are also important. The outcome ranges from complete recovery to progression of symptoms, which often includes secondary osteoarthritis or collapse of the affected area. Research has shown that flattening of the affected condyle on radiographs is always associated with progression. However, if caught early and if the symptoms are managed effectively, the outlook for SONK is good with a high chance of complete resolution.

Conclusions

SONK is a rare condition within the orthopaedic field and little is known regarding the aetiology, pathophysiology or treatment efficacy. Low incidence and frequent under-investigation or misdiagnosis

mean there is limited published data, which is often from small retrospective studies. Due to the progressive nature of the disease process untreated controls are not possible, so there are few prospective studies. In addition, differences in staging schemes and classification of proposed aetiology of enrolled patients, plus subjective quantification of clinical and radiographic findings, means findings of different studies are often not comparable. The limited availability of data combined with difficulties carrying out randomised controlled trials means there is no established 'best practice', and treatment of individual patients is often based on anecdotal evidence. This information sheet aims to summarise and raise awareness of current thinking on aetiology, diagnosis, management options and prognosis.

Illustrations

MRI of a 55 year old male with spontaneous onset pain in the medial femoral condyle



Image intensifier view at the time of core decompression

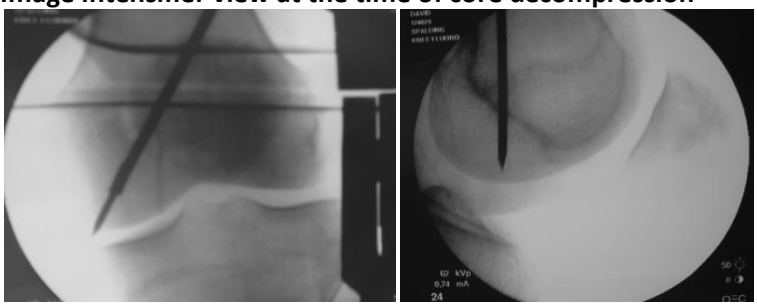

MRI after 6 months showing the changing in marrow signal and the healing tracks.



Researched and written By Katie Bonner and Leila Makhani, Medical Students

For the knee team at University Hospital Coventry and Warwickshire NHS Trust: Tim Spalding, Pete Thompson and Mark Taylor, Consultant Orthopaedic Surgeons.
January 2012